



**Southern
Cross Dental**
Great care. Great practice.

SCD CASE STUDY

Treatment Considerations for Implant Rehabilitation

“Multiple surgical and restorative factors play a role in the treatment planning of implant restorations for the edentulous patient (Ali B, Bhavani V., 2014)”.

Critical restorative factors include a complete examination and evaluation of:

- • Hard and soft tissues
- • Need for lip support
- • Location of occlusal plane
- • Available restorative space
- • Number, position and angulation of implants (Stamford CM., 2005).

Criteria to be used as design principles critical to the fabrication of implant framework may include sufficient access for oral hygiene, mechanical strength and the least amount of visible metal on the buccal and occlusal surfaces (Lin WS., 2014). However, the bulk of the frameworks are smaller and cantilevers should be avoided. The precision of the framework fit is essential for optimal screw mechanics. Several longitudinal clinical studies have shown that poorly-fitting frameworks may be one of the main causes of screw loosening or fracture, abutment fractures and even implant fractures (Jemt T. et al., 1994).

Several materials have been used in the manufacture of implant frameworks which include:

- Noble metals
- Base-metal alloys
- Titanium and its alloys

The choice of metal is largely dependent on the casting accuracy, hardness, modulus of elasticity and handling properties. Metal-ceramic fixed units require more implants to support the restoration for biomechanical, technical and ease of maintenance issues.

One of the main determinants of the type of implant restoration for the edentulous patient is the restorative space. Implant-retained fixed dental prostheses and bar overdentures require at least 13-14 mm between the crest of the ridge and the occlusal plane. Overdentures retained by Locator (Locator®; Zest Anchors) attachments require at least 8.5 mm (Sadowsky SJ., 2007).

Other factors which determine prosthetic success are implant location and angulation, which depend on the tooth position. The determination of tooth position is an essential part of the diagnostic process. If the patient presents with a well-fitting and aesthetically pleasing existing complete denture prosthesis, it can often be duplicated and used as a radiographic and surgical guide for implant placement. If the prosthesis is not acceptable, a

diagnostic wax-up and new interim prosthesis should be made which can be evaluated for aesthetics and phonetics prior to surgery. The implant surgery must be planned in conjunction with a complete restorative work-up so that the prosthetic outcome is as optimal as possible.

History

A female patient aged 62 presented to the practice. The main concerns were that she had been wearing the same full upper denture for 40 years. There were still 2 third molars in the upper jaw that were worn down to the gum line. Nine teeth were present in the lower jaw, which were deemed unsalvageable. The patient expressed a desire to have the lower teeth removed and new full upper and full lower dentures constructed. The patient's wish was not to have to go to the dentist again.

The dentist discussed expectations of treatment outcomes with the patient and what the patient's long-term goal was for her teeth. There were clear objectives to have better masticatory function, aesthetic requirements, improved speech and an improved sense of well-being. The patient reported that three anterior teeth exfoliated naturally in the last 3 weeks and chewing was not problematic but the loss of the teeth had resulted in a lisp. The existing full upper denture had not been a problem over the years. Breakages had occurred with the denture which was repaired by gluing the denture.

The presenting condition is viewed in FIG. 1a, b, c and d.

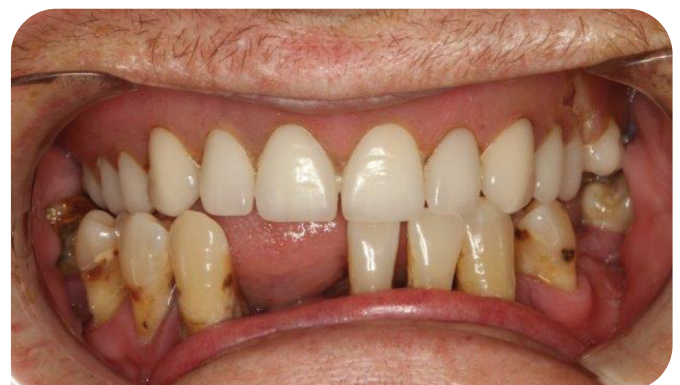

FIG. 1a Frontal view

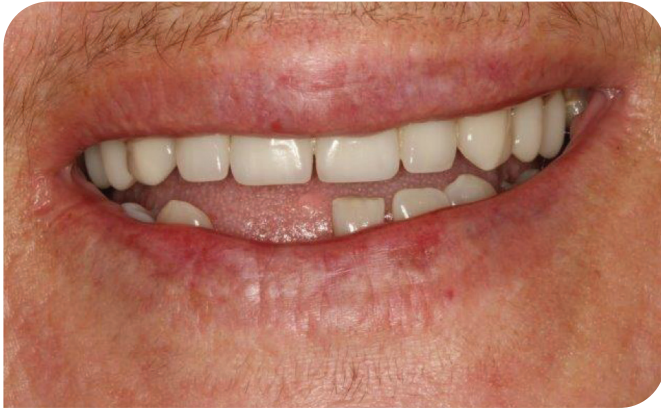

FIG. 1b Frontal view-smile

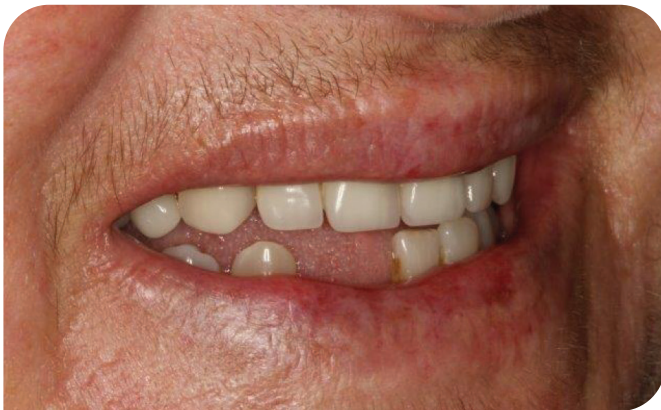

FIG. 1c Right lateral

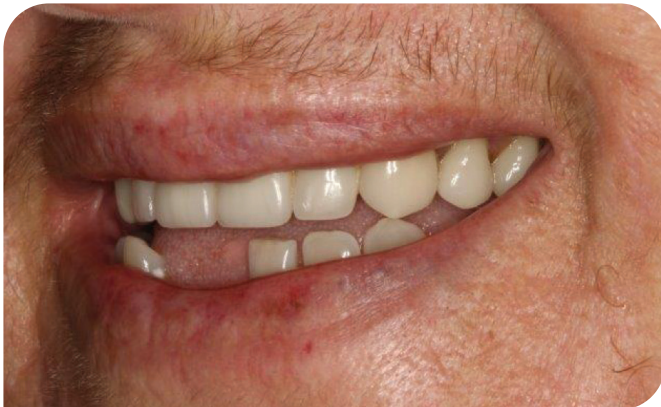

FIG. 1d Left lateral

Examination

The periodontium was examined and the periodontal measurements revealed 3 - 4 mm generalised probing depths. The lower anterior teeth showed grade 2 mobility. The diagnosis was severe adult periodontitis with a very poor prognosis.

The soft tissues and lymph nodes were examined and checked and found to be unremarkable, indicative of a clear oral cancer screening check.

The maxillary arch was examined and there was good bone height. Dimensionally, the jaw was narrow and the patient was advised to replace the upper denture and slightly increase the vertical dimension of occlusion so that more tooth structure would be evident aesthetically.

Radiographic Findings

The initial panoramic radiographic revealed irreversible destructive periodontitis. A significant periapical lesion was noted on the lower left mandibular molar (FIG. 2).

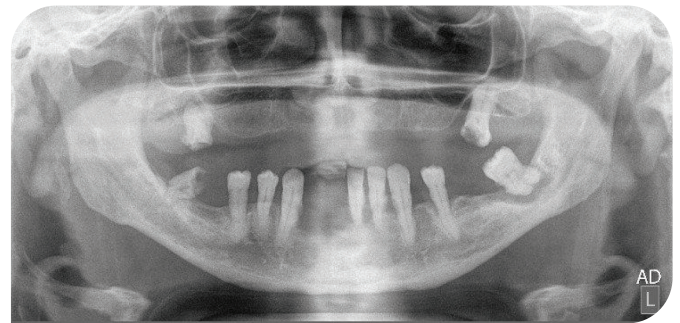


FIG. 2

Treatment Options

The following treatment plan options were presented:

1. Full Upper Denture
2. Fixed implant-supported overdenture
3. Full Upper Denture with 3 or 4 implants removable

Lower Options

1. Full Lower Denture
2. Full Lower Denture with 2 or 3 implants to support the denture as a removable
3. Fixed implant-supported overdenture

Clinical Procedures

Visit 1 (Implant placement and prosthetic stabilisation - FIG. 3a-3d)

- LA Used: Articaine 4% 1:100000 Adrenalin 10.8 mls inferior dental block Quadrant 3 Quadrant 4
- Buccal flap raised Performed osteotomy to insert implant
- 35: MIS 3.75 x 8mm Seven internal hex LOT:WO2196421 Torque 50Ncm
- 45: MIS 3.75 x 8mm Seven internal hex LOT:W13000918 Torque 50Ncm
- Coverscrew placed
- Sutured using Chromic Gut 5/0

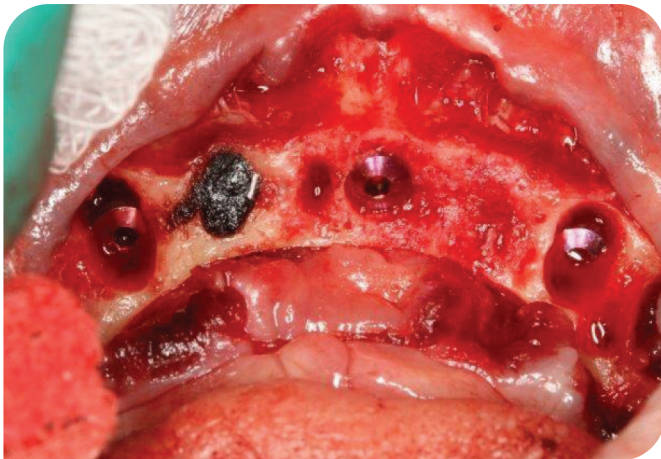


FIG. 3a Implant placement

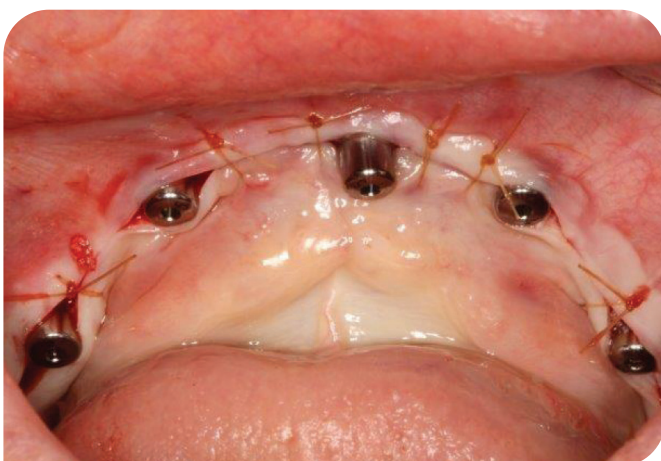

FIG. 3b Occlusal view of edentulous mandible with healing abutments in place.

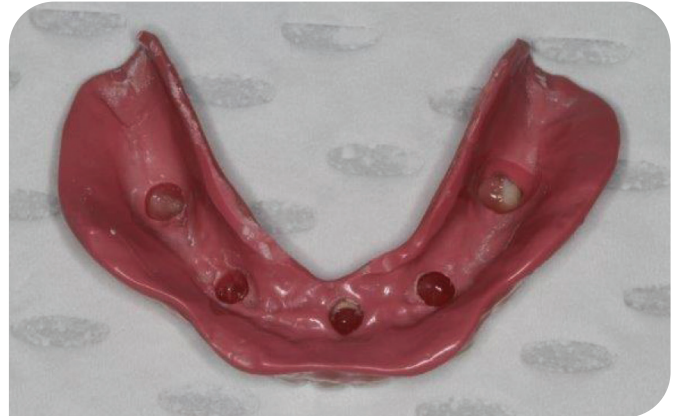

FIG. 3c The existing mandibular denture

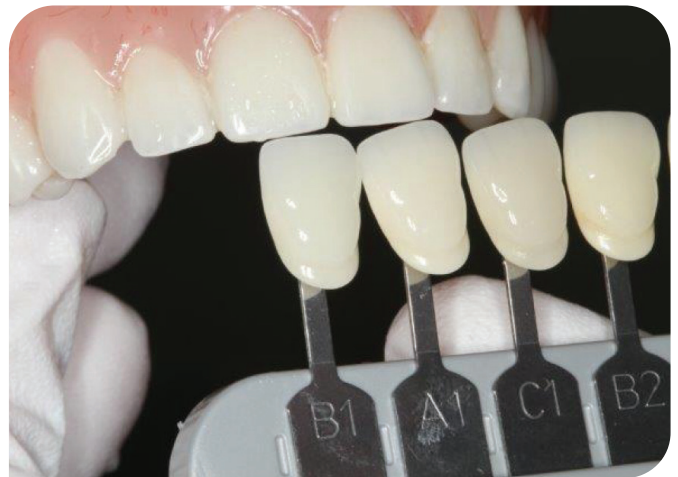

FIG. 3d Shade selection with existing was relieved, relined and repolished. denture

Visit 2 (impressions for provisionalisation – FIG. 4a-4d)

- Removed healing abutments and placed MIS pick up impression copings into 45, 43, 31, 33, 35
- Lower impression using Affinis® (COLTENE) heavy and light body PVS
- Replaced healing caps
- Took upper alginate for special tray and bite block for new Full Upper Denture
- A combination approach of both screw and cement-retained restorations both in the intermediate prosthesis and the final porcelain-fused-to-metal final restorations was employed
- Fixed provisionalisation was deemed necessary to ascertain functional, aesthetic and phonetic performance

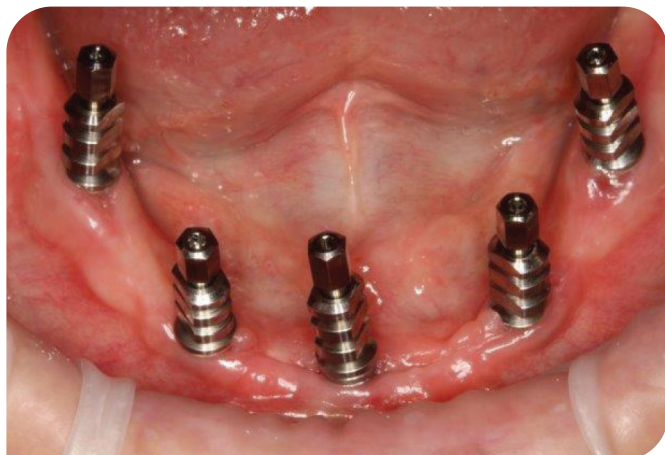

FIG. 4a Pick-up impression coping in place

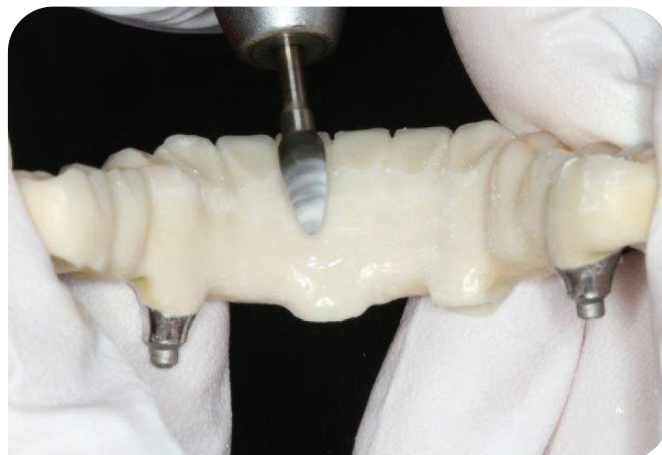

FIG. 4d Laboratory made provisionals for the fabrication of the restorations.

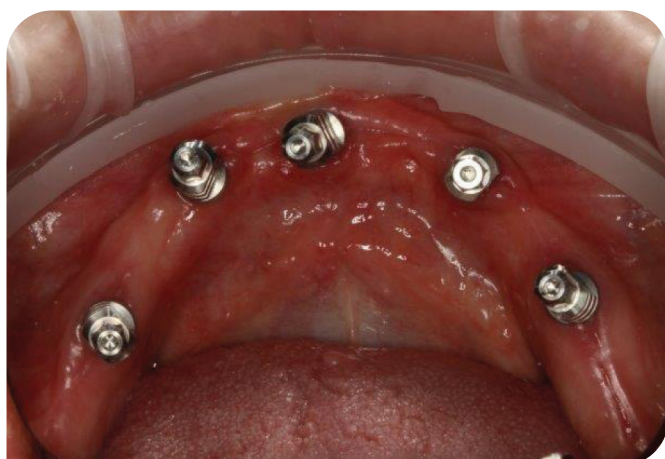
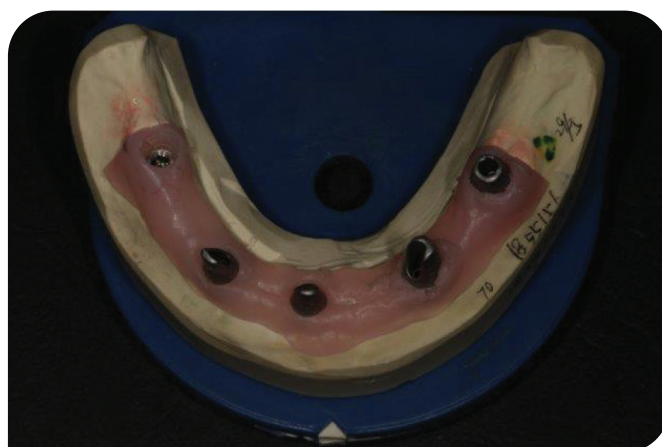
FIG. 4b Occlusal view of impression copings



Visit 3 Fabrication of abutments (FIG. 5)

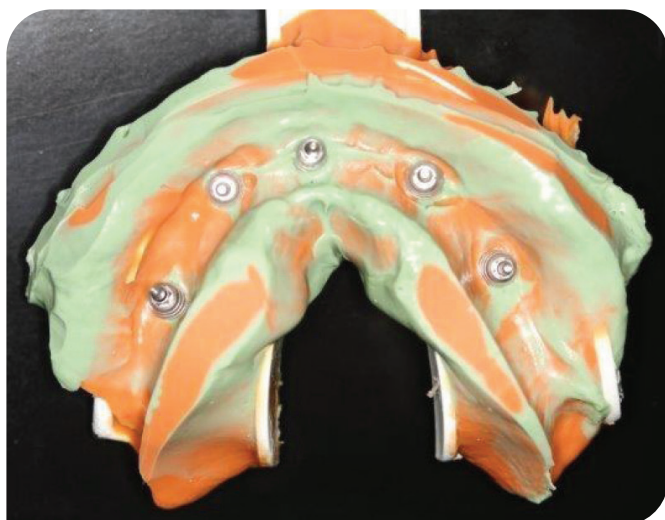

FIG. 4c Open-tray impression technique

Visit 4 Try-in of abutments and verification index (FIG. 6a-6c)

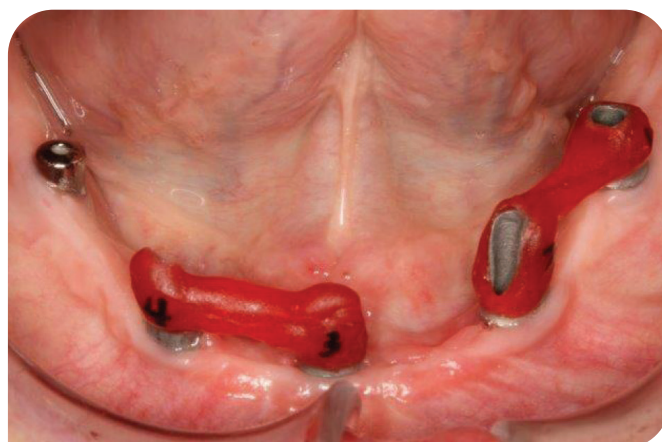


FIG. 6a

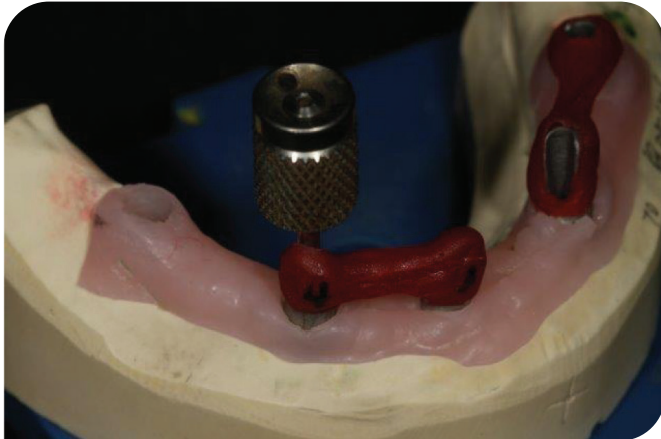


FIG. 6b

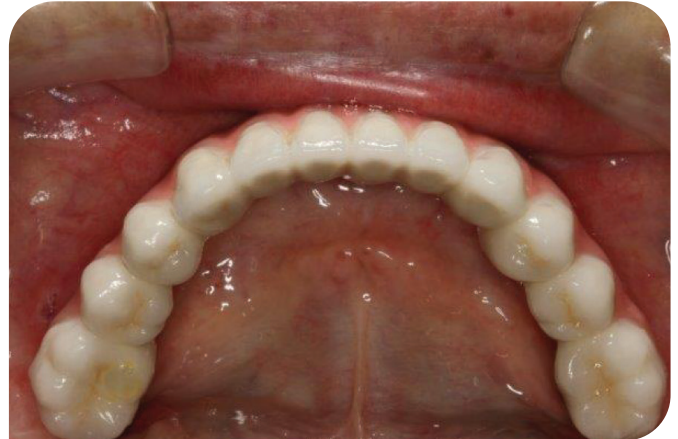

FIG. 7b

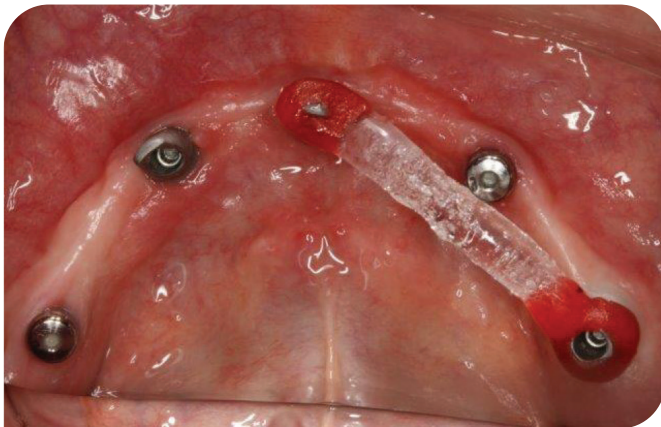


FIG. 6c

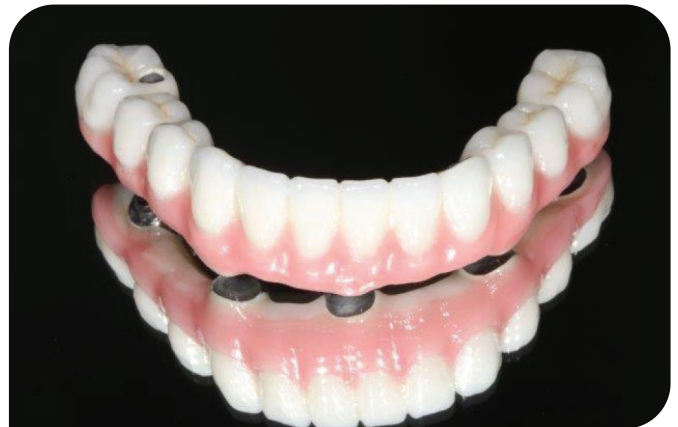

FIG. 7c

Visit 5 Try-in and final issue (FIG. 7a-7c, 8a-8b)

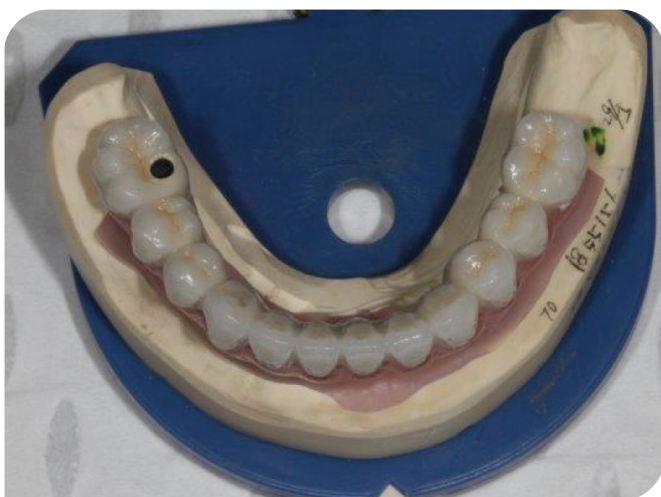

FIG. 7a

- The implant bridge was inserted and checked, and the patient and dentist were happy with shape, shade and fit. The prosthesis was issued on the same day and screwed in on the right hand side to 32Ncm
- The bridge was cemented onto the abutments using Freegenol™ NE (GC America)
- The access hole was sealed with silicone tape, ceramic etch, metal primer, Calibra™ silane, Clearfil™ SE bond, bellglass opaque, A1 flowable and P-A1 G-ænial composite (GC Europe)
- Temporary cement was used on the abutments to achieve a passive fit and a screwretained restoration was included in the prosthesis so that it did not fall out
- The occlusion was checked and adjusted, and then polished

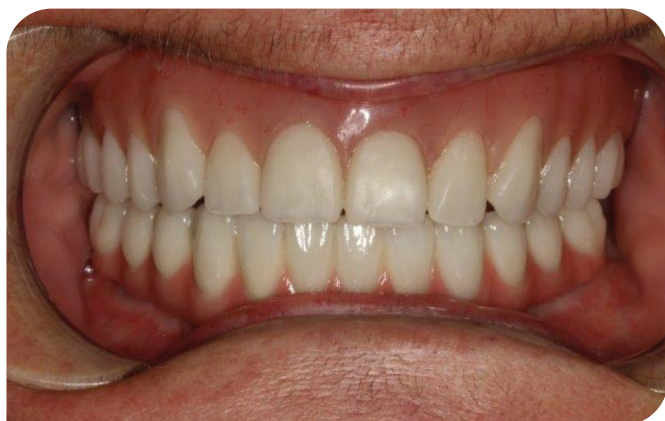

FIG. 8a

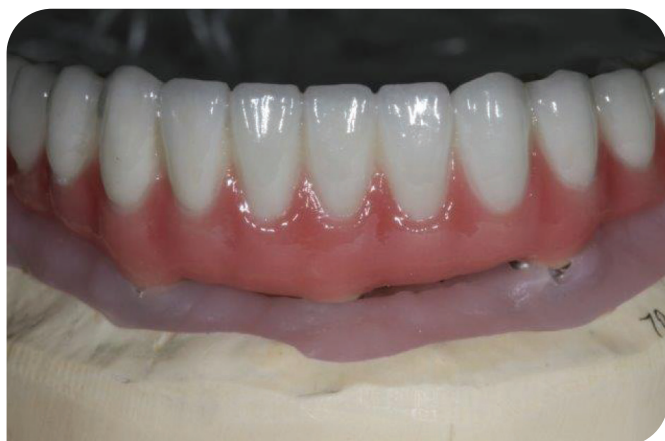

FIG. 8b

Southern Cross Dental would like to acknowledge and thank Dr Lincoln Harris, Bargara, Queensland for the presentation of this clinical case.