



**Southern
Cross Dental**

Great care. Great practice.

SCD CASE STUDY

Implant Rehabilitation

Dental implants offer an effective and predictable way to replace teeth. Function, aesthetics and phonetics are regained. The long-term success clinically and aesthetically depends upon an appreciation and management of the peri-implant tissues.

Predictable osseointegration factors include (Tagliareni JM, Clarkson E., Dent Clin N Am, 2015):

- Atraumatic surgery
- Placement of the implant with initial stability
- Immobility of the implant

The ability of the integrated implant to bear a load must be greater than the anticipated load during function.

It is the responsibility of the dentist to address the patients concerns, fears and expectations of treatment and outcome of treatment. Managing expectations is critical to achieve realistic outcomes for both the dentist and the patient. "Patients should be informed of the spectrum of potential complications and maintenance issues that can occur with implant-borne prostheses and informed of the biological consequences and associated future costs" (Lewis MB. and Klineberg I., Australian Dental Journal, 2011).

The pre-operative assessment should include:

- Chief presenting complaint
- Medical history and risk assessment
- Dental history
- Intraoral evaluation – hard and soft tissues, jaw relationships, parafunction
- Diagnostic casts and photographs
- Radiographic examination – pre-surgical imaging allows clinicians to determine quality and quantity of available bone

At the time of the examination the charting should include (Klein M., Atlas of Minor Oral Surgery, 2001):

- Status of remaining teeth
- Mobility
- Furcations
- Periodontal probing depths
- Keratinised tissue
- Interarch space
- Distance between the teeth
- Ridge width
- Supraeruption
- Tilted teeth
- Occlusal/incisal plane
- Smile line
- Appearance of soft tissue in the smile
- Number of teeth in a wide smile
- Aesthetics of existing teeth
- Presence of any infection

The predictability of the aesthetic outcome of an implant restoration depends on (Jivrai S. et al., J Implant Pract, 2013):

1. Patient selection and smile line
2. Tooth position
3. Root position of the adjacent teeth
4. Biotype of the periodontium and tooth shape
5. Bony anatomy of the implant site

Case Study

The patient presented to the surgery after a football accident when he was knocked in the mouth (Fig. 1). The trauma and pain caused the patient to present to the local hospital for pain relief.

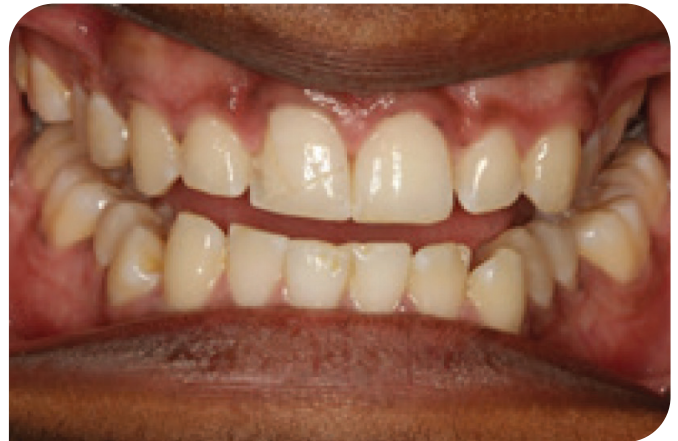

FIG. 1

Upon attendance at the surgery, the patient complained of severe pain and sensitivity to cold and air. On examination there was a crack in the tooth which had occurred at an angle and was inclined towards the root of the tooth. An OPG was taken (Fig. 2).

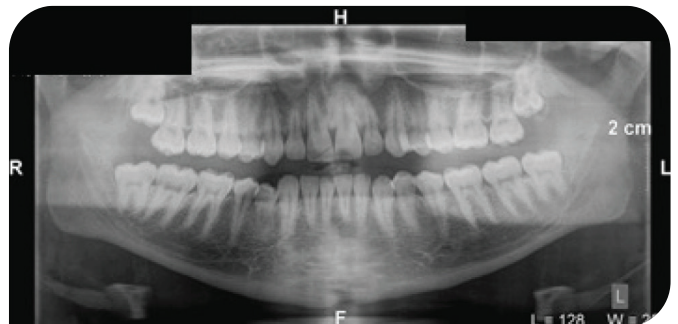


FIG. 2

The patient was advised that the tooth was unable to be saved. As a result of potential bone infection, the patient was advised to seek prompt treatment as if the tooth was left for too long then bone could be lost. A warning was given that some type of graft may be required.

Various treatment options and costings were presented to the patient:

1. Bridge
2. Partial upper chrome
3. Implant

After the treatment plan discussions, the patient opted to have the implant. The relevant literature from the ADA was given to the patient.

Procedures

1. Implant placement

Scandonest 3% was employed with 1.8ml buccal infiltration and Articaine 4% 1:100,000 adrenalin 1.8ml buccal infiltration and 1.8ml palatal infiltration.

An alginate impression was taken to make an essix retainer with a tooth. Elevators and forceps were used to remove 11.

The bone was prepared for placement of an implant into 11 socket. The implant placed was IA43-12d-13 4.3 mm X 13 mm TRI-NEX CO-AXIS 12 degree angled (LOT 084D04d2n02) which was torqued to 50Ncm. A 3.5 X 3.0 mm WIDE healing abutment was placed. Bio-Oss .25g graft was placed around the implant and into the socket to keep the ideal gum shape. The Bio-Oss and top of the implant were covered with Cytoplast™ GBR-200 membrane to help keep the bone graft material intact. The socket area was sutured to keep the membrane in place (Fig. 3).

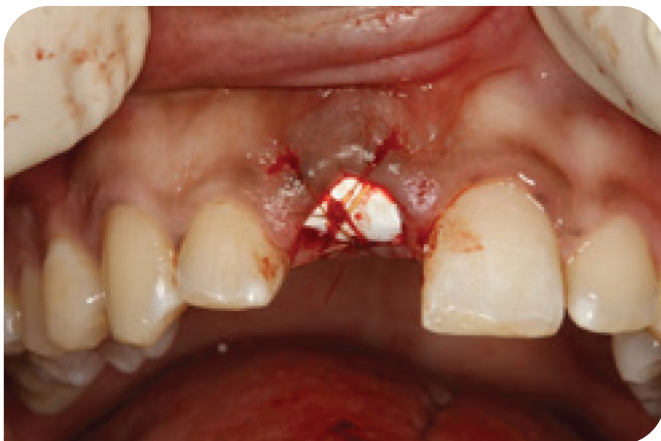

FIG. 3

An essix retainer was provided for the patient later in the day. Panadol and Nurofen were given post operatively and the patient was advised that the bone graft material would have a white sandy texture. The

patient was asked to avoid eating anything hard or crunchy for the next week or so.

2. Stabilisation

This was scheduled for 2 months after the implant had been placed (Fig. 4a and 4b).

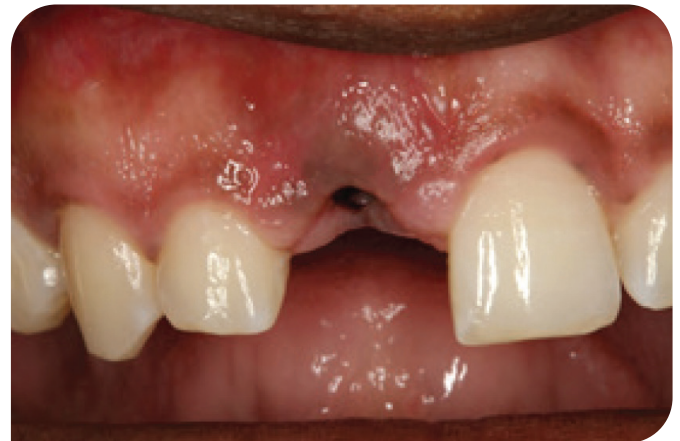

FIG. 4a

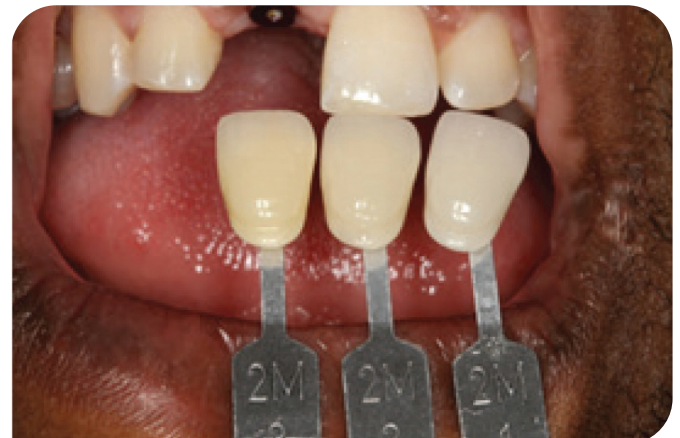

FIG. 4b

An impression of the implant was done and no local anaesthetic was required. A shade was taken -2M1 2M2 2M3. The healing abutment was removed and a 3.5 mm impression coping was placed. The radiograph showed that all looked good. Upper and lower polyvinylsiloxane impressions were taken using AFFINIS® heavy and light body. The occlusal registration was taken using Blue Velvet for 30 seconds.

An explanation of the difficulty of colour matching a single anterior tooth was necessary to ensure the patient understood early reporting back to the dentist if the aesthetics were not excellent. The temporary crown was to be fabricated at the laboratory. The patient understood the need for the provisional restoration to allow ideal tissue recontouring.

3. Insertion of provisional crown

Local anaesthetic was used Articaine 4% 1:100,000 Adrenalin 1 mls buccal infiltration palatal infiltration quadrant 1. The healing cap was removed and a temporary crown placed on 11 to 32Ncm (Fig. 5).

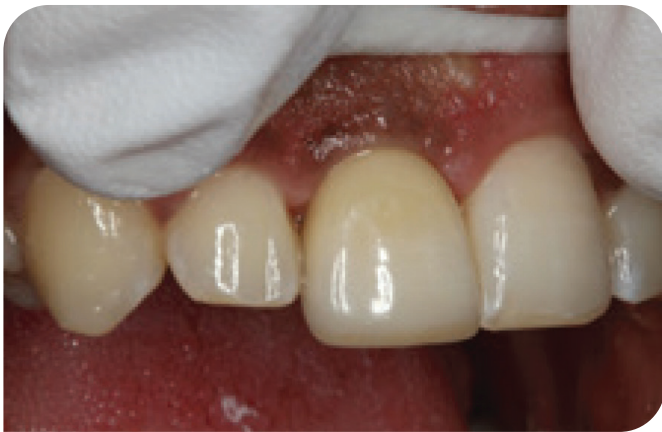

FIG. 5

The access hole was filled using silicone tape. Metal primer Surpass® 2 and 3 (self-etching bonding system) and CLEARFIL MAJESTY™ Flow A2 G-aenial™ P-A2. The occlusion was checked, adjusted and polished. Post-operative Panadol was advised.

4. Definitive crown placement – step 1

A new impression was taken two months later. The gum had remodelled nicely around the gingival margin. Once the temporary crown was removed, the top of the implant was cleaned and the surrounding gum was irrigated with Savacol. A 3.5 mm impression coping was used to take an impression with AFFINIS® heavy and light body silicone. The temporary crown was reinserted and the access hole filled with plumber's tape, surpass and A2 flowable and polished.

5. Final crown placement

The shape of the crown was evaluated at the beginning of the visit. The patient and the dentist were happy with the shape and shade of the crown. The new implant abutment crown was screwed in to 35Ncm and the crosspin tightened (Fig. 6).

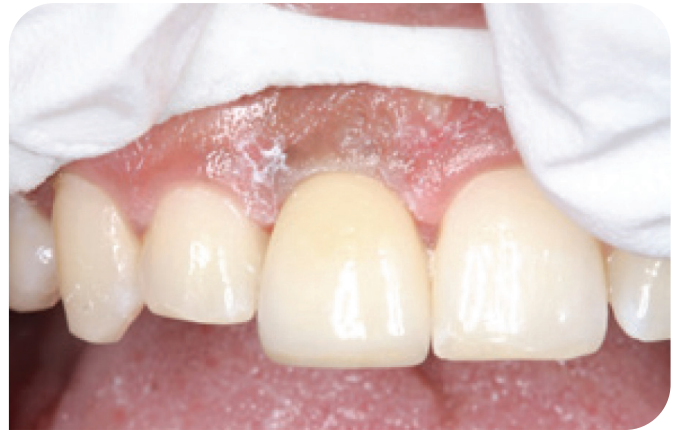

FIG. 6

At a subsequent appointment, the opposing 42 was adjusted by 0.5 mm. Tooth 42 was anaesthetised with Articaine 4% 1:100,000 Adrenalin 1.8 ml by buccal and lingual infiltration in the 42 area.

The 42 was checked and adjusted to ensure that the 42 was not hitting hard on the 11 crown.

The 42 was sealed using GLUMA® and CLEARFIL™ SE BOND. It was critical to ensure that no deleterious forces were placed over the implant. The screw was tightened on the 11 implant.

“Overload caused by improper prosthesis design or parafunctional habits is considered to be one of the primary causes of late-stage implant failure” (Balshi TJ., The International Journal of Oral & Maxillofacial Implants, 1996).

Southern Cross Dental would like to thank Dr Lincoln Harris, Bundaberg, Queensland for provision of this clinical case.